

Posterior Reversible Encephalopathy Syndrome as a Rare Pediatric Complication

¹Abdu H. Mashhour, ²Mohammed H. Hakami, ³Hassan M. AlMalki, ⁴Haleemah M. ALQassimi, ⁵Ali A. Refaei, ⁶Essa W. Magfori, ⁷Mohammed A. Sulaiman, ⁸Mohammed A. Homood, ⁹Abdulrahman A. Khawaji, ¹⁰Reham M. GHobain, ¹¹Yahya H. Ghazwani, ¹²Magbul H. Maghfuri, ¹³Magda A. KHazbak.

Abstract— Posterior reversible encephalopathy syndrome (PRES) is a neurotoxic state coupled with a unique radioimaging appearance . (PRES) refers to a disorder of reversible brain vasogenicoedema in patients with acute neurological symptoms. Its clinical manifestations include seizures, visual disturbances, headache, confusion, impaired consciousness, ataxia, and other focal neurological signs. It is a complex and multidisciplinary disease with the pathophysiological changes still controversial. Therefore, clinical and neuro-imaging judgment seems so crucial. Here we report a case of a five- year- old boy who was admitted with dengue fever that later progressed to PRES

Index Terms— Dengue fever; Encephalopathy; posterior reversible encephalopathy[PRES]

Introduction:

It has been almost twenty years since the report by Hinchey et al(1), which first reported a case with PRES. It is characterized by a variable association of seizure ,headache, vomiting , visual disturbance and impaired consciousness .Since the report by Hinchey at al (1) PRES has been associated with many other clinical conditions as hypertension , infections , drugs, autoimmune disorders , kidney disease and hematologic disease. (2). This is a topic of growing interest among pediatricians. PRES is a complex and multidisciplinary disease, the symptoms and signs are nonspecific with no guidelines to direct this assessment. Therefore, clinical and **neuro-imaging** judgment seems so crucial, and it should be considered in patients who present with any neurological deficits. Usually, the white matters in the bilateral parieto-occipital regions are the main affected areas, which generally appear high-intensity on T2-weighted and FLAIR images.(3)

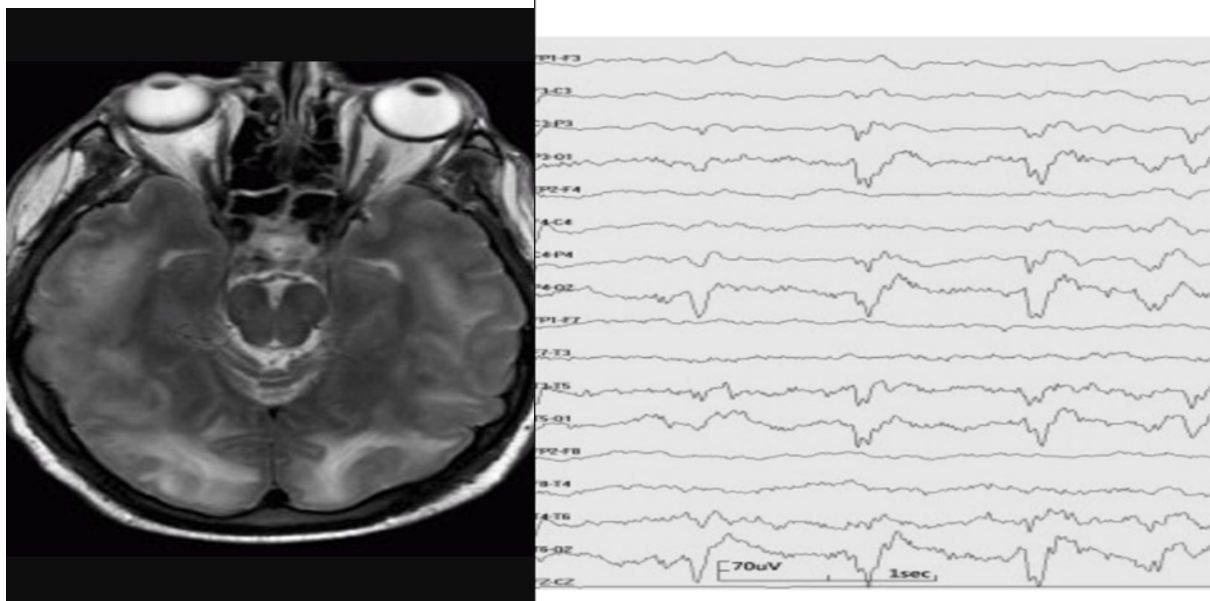
Case Summary:

A 5- year-old Saudi boy who was medically free before, was referred to our hospital (King Fahd Central Hospital, Jazan KSA) due to headache ,semi consciousness associated with fever for one week. On examination, his blood pressure was normal.GCS deteriorated to3/15.No other marked neurological deficit, nil else. In PICU ,he was intubated and ventilated , with a picture of severe encephalopathy,sepsis and multi-organ failure.

Diagnosis and management :

CBC , serum electrolytes and metabolic screen were normal. His lab tests were showing liver and renal derangement with negative viral screening ,except positive results of dengue virus[IgM antibodies, IgG antibodies and Dengue viral protein:the non-structural protein 1 NS1ELISA,were all high in serum] A prolonged PT ,PTT were detected , blood culture was negative , toxicology screen was negative with normal CSF results. Chest X-ray was also normal. After one week in PICU , patient was extubated and was maintained on room air. The child showed abnormal up- rolling of eyes, recurrent, for few seconds each time, not preceded by any triggers and not proceeding to other abnormal movements. Seen by pediatric neurology consultant, diagnosed as subtle convulsions and placed the patient on carbamazepine after EEG. The ophthalmologist reported there was central blindness. Consultant pediatric neurologist diagnosed the case as PRES as his EEG showed abnormal occipital waves[as shown in figure],and after imaging the brain by MRI[shown in figure].

His brain MRI showed:Multiple cortical-subcortical areas of T2 -weighted hyperintensesignal involving the occipital and parietal lobes bilaterally and pones regions with vasogenicoedema



After five days, the abnormal eye movements stopped, the child was able to see again, having restored his normal vision. So, and based on all these findings, he was diagnosed as PRES that complicated dengue virus infection.

Discussion:

The clinical spectrum of PRES is characterized by acute encephalopathy with headache as the most common symptom, with the characteristic feature of reversibility. PRES is a rare neurological condition of pediatric age group, that is diagnosed by both clinical and radiological data. Although the mechanism has not been fully elucidated, endothelial dysfunction injury leading to vasogenic edema and decreased cerebral blood flow is the main reason (4). The etiology varies widely between hypertension, medication, autoimmune disorder, cardiac and hematological causes, renal causes and post transplant status. Infections include virus, bacterial, gram positive sepsis, gram negative sepsis like E.coli and septic shock. To the best of our knowledge, no previous case reported with PRES following dengue virus infection. Treatment involves mainly correction of causative factor (5).

Our case presented with headache, decreased level of consciousness, seizure and cortical blindness, following dengue fever, but complete reversibility of the condition together with EEG and brain MRI findings guided us to diagnosis of PRES (6).

MRI is particularly useful in the diagnosing of PRES. Radiographic stigmata usually involve increased signal on T2 and fluid attenuated inversion recovery (FLAIR) imaging of sub cortical white matter with vasogenic edema predominately involving the parieto occipital and posterior temporal lobes (7).

This case highlights the pontine distribution of PRES. The differential diagnosis included central pontine myelinolysis, ischaemic, radiation toxic effect, and pontine glioma that usually exhibits expansion and mass effect. All are irreversible, unlike our case (8).

The term PRES is a misnomer, as it occurs not always in posterior cerebral circulation, but may occur primarily in anterior cerebral circulation. Also, PRES is not always reversible, it can be rarely irreversible if there is delay or neglect of treatment (9), (10).

This case widens the differential diagnosis for conditions predisposing to PRES. Pediatricians should be aware of this potential association between dengue encephalopathy and PRES. A high index of suspicion is needed for a good outcome related to early recognition and appropriate intervention (11).

Conclusion:

In conclusion, PRES may complicate the course of dengue fever, and may be more frequent than reported. This syndrome has broad clinical spectrum and MRI features. We recommend EEG monitoring for detecting subtle electrographic seizure in children with suspected PRES. An early and a follow up brain MRI are mandatory for diagnosis. The rapid resolution of clinical status with supportive treatment helps in differentiation from other causes of encephalopathy. Early diagnosis can be accomplished if pediatricians hold it in the background of their minds, and it is always for the best interest of the patient.

References

- (1) [Hinchey Y](#), Chaves C, Appignani B, Breen Y, Pao L, Wang A, et al. A reversible posterior leucoencephalopathy syndrome. *N Engl J Med.* 1996;334: 494-500.

- (2) [Bartynski](#) WS, Boardman YF , Zeigler ZR, Shaddock PK, Lister Y. Posterior reversible encephalopathy syndrome in infection, sepsis, and shock. *AJNR AM JNeuroradiol.* 2006 ; 27: 217-90.
- (3) [Kastrup](#) O, Maschke M, Wanke I, Dienes HC. Posterior reversible encephalopathy syndrome. *JNeurol* 2002; 249: 1563-6.
- (4) Kwon S, Koo Y, Lee S. Clinical spectrum of reversible posterior leucoencephalopathy. *Pediatr Neurol.* 2001; 24: 361-4.
- (5) McKinney AM, Short Y, Truit CL, McKinney ZY, KozakOS,SantaCruzKsm at al. Posterior reversible encephalopathy syndrome : Incidence of atypical findings in a child with hypertension . *Ann Indian AcadNeurol .* 2015; 15:208-10.
- (6) [Kostic](#) D, Yovanovski A, SekulovicL . Posterior reversible encephalopathy syndrome . *J NeurolTransLNeurosci.* 2013;1(3): 1023.
- (7) [Fugate](#) YE, Rabirstin AA. Posterior reversible encephalopathy syndrome: clinical and radiologic manifestations, pathophysiology and outstanding questions. *Lancet Neurol* 2015; 14: 914-25.

- (8) [Raul](#) KM, Wawal M, GrudkanSh, Mogal V. Posterior reversible encephalopathy syndrome (PRES): Report of three cases with brief review of literature.*Journal of Dental and Medical Sciences (IOSR-JDMS)* 2013;8(3): 45-48.
- (9) [KailLi](#) DD, Li G, Long X. Posterior reversible encephalopathy syndrome following paroxysmal nocturnal hemoglobinuria: A case report and literature review. *Am J ClinExp Med* 2015;8 (7):11617-11620.
- (10) Pugliese S, Finochi V, Borgia ML, Nania C, Della VellaVella B, Rierallini A, Bozzao A. Intracranial hypotension and PRES: Case report. *J Headache Pain .*2010; 11(5): 437-440.
- (11) [Graham](#) BR, Pylypchuk GB. Posterior reversible encephalopathy syndrome in an adult patient going peritoneal dialysis: A case report and literature review. *BMJ Nephrology.* 2014; 15:10.

IJSER